

Large uterus: what is the limit for a laparoscopic approach?

Beatriz H. Kehde^{a,b}, Bruno J. van Herendael^{b,c}, Benedictus Tas^c, Deepika Jain^{b,d},
Karine Helsen^c, Lisbeth Jochems^c

Kehde BH, van Herendael BJ, Tas B, Jain D, Helsen K, Jochems L. Large uterus: what is the limit for a laparoscopic approach? *Autopsy Case Rep* [Internet]. 2016;6(1):51-56. <http://dx.doi.org/10.4322/acr.2016.025>

ABSTRACT

Hysterectomy is the most common surgical gynecologic procedure, which is frequently related to the treatment of leiomyoma. The laparoscopic hysterectomy is associated with a shorter hospital stay, fewer infection rates, and a faster return to daily activities. Most gynecologists do not recommend a hysterectomy via the vagina or a laparoscopic-assisted vaginal hysterectomy (LAVH) in the case of a uterus weighing more than 300 g. This case report presents the case of an LAVH undertaken in a 43-year-old patient with a uterus weighing 2,800 g. There are no definite guidelines concerning the procedure for a large uterus, and the literature is vague regarding the best surgical procedure for these cases. The size of the uterus does not seem to be an absolute contraindication for endoscopic surgery. This procedure relies entirely on the surgeon's ability.

Keywords

Hysterectomy; Vaginal; Uterus; Leiomyoma

INTRODUCTION

Hysterectomy is the most common gynecologic surgical procedure performed in the United States, accounting for 600,000 procedures per year.¹ The most common indication for a hysterectomy is abnormal uterine bleeding, which is frequently caused by uterine leiomyoma,² which is present in 25-50% of reproductive-aged women.³ In 2003, approximately 66.1% of hysterectomies performed in the United States were via the abdomen; 21.8% were via the vagina; and 11.8% were laparoscopically undertaken.⁴

A meta-analysis by the Cochrane Library showed that both the vaginal and the laparoscopic hysterectomies were associated with a shorter

hospital stay, fewer infections, and a more rapid return to normal activities compared with abdominal hysterectomies.⁵ Furthermore, the former is associated with less postoperative pain, a faster recovery, and a better cosmetic result.⁶ Wattiez et al.⁷ concluded that "the rationale for hysterectomy is to convert abdominal hysterectomy into a laparoscopic procedure and thereby reduce trauma and morbidity."

In 1989, Reich and DiCaprio⁸ performed the first total laparoscopic hysterectomy (LH). Since then, several authors have reported their experience with this operation, so much that LH is currently accepted as

^a Department of Obstetrics and Gynecology - Santa Casa de Misericórdia de São Paulo, São Paulo/SP – Brazil.

^b Endoscopic Training Centre – Antwerp – Belgium.

^c Ziekenhuis Netwerk Antwerpen ZNA Stuivenberg, Sint Erasmus Department Gynecological Endoscopic Surgery, Antwerp – Belgium.

^d Department of Obstetrics and Gynecology - Anand Hospital, Beawar/Rajasthan – India.



a safe procedure for the treatment of benign uterine pathology.⁹

The term “large uterus” has been overused. In several publications, this term was used to define the weight of a uterus > 300 g or > 500 g.¹⁰⁻¹² Giant myomas usually obstruct the pelvis and become extremely difficult to be mobilized and manipulated, reducing the availability to identify the surrounding anatomic structures, and hampering the correct development of the spaces by the surgeon. In the study by Uccella et al.¹³ comprising more than 1,500 hysterectomies, the prevalence of uteri weighing > 1 kg was 5.7%.

Studies involving the laparoscopic procedure for the treatment of a uterus weighing > 1 kg are scanty and involve a small number of patients,¹⁴⁻¹⁶ and the procedure via the vagina has been limited to sporadic reports.¹⁷ The case reported herein presents the removal of a 2,800 g uterus via laparoscopic-assisted vaginal hysterectomy (LAVH) by skilled surgeons using minimally invasive techniques. The report was approved by the ethics committee of the hospital (ZNA Stuivenberg/ Antwerp - Belgium), and was formally consented by the patient. This intervention was part of a routine treatment—hysterectomy—

hysterectomy. The informed consent had been obtained from the patient.

CASE REPORT

A 43-year-old woman born in the Middle East presented to the medical facility complaining of a “large ball” in the abdomen for 2 years, which was associated with nocturia. She denied abnormal uterine bleedings, but eventually presented pain. She was obese (body mass index = 34.5kg/m²) but no other comorbidity was present. Physical examination revealed a mobile, painless, pelvic-abdominal mass extending 3 cm above to the umbilicus.

Abdominal and vaginal ultrasonography was performed showing a large mass in the uterine topography that was scarcely vascularized and sized 13.9 × 16.4 cm.

The magnetic resonance images showed a mass with areas of hyperintense signal intermingled with areas of hypointense signal in T2 in the fundus and the posterior wall of the corpus uteri partially subserous and intramural. The mass measured 18.7 × 16.3 × 21 cm. The endometrial cavity was normal (Figure 1). These findings were consistent with

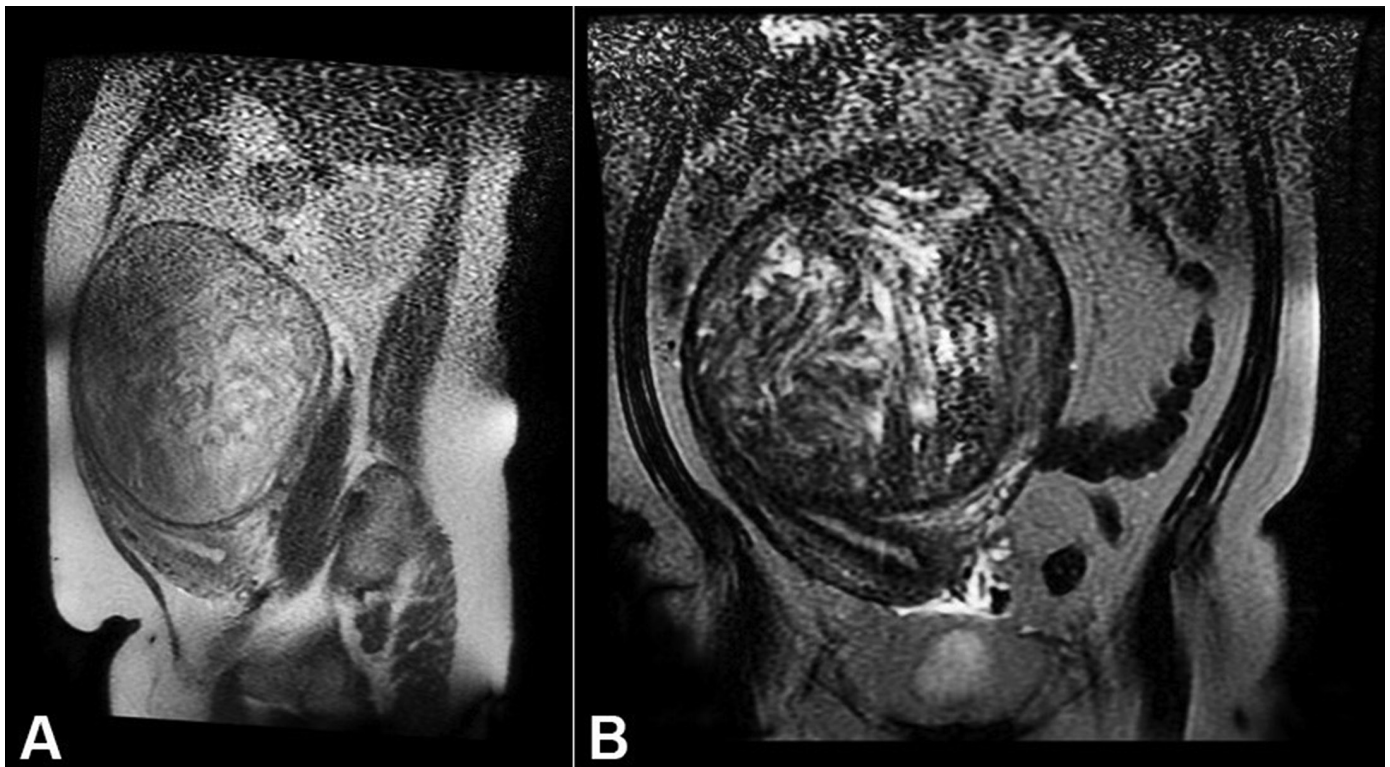


Figure 1. Magnetic resonance of the abdomen. T2 weighed images showing a uterine nodule partially subserous and partially intramural. **A** - Sagittal plane; **B** - Coronal plane.

the diagnosis of uterine myomatosis without any sign of malignancy.

The patient was submitted to LAVH. To reach the pneumoperitoneum a Veress needle was placed in the Palmer point. Via an incision of 1.5 cm, a 5 mm trocar was inserted followed by a 5 mm zero degree laparoscope (Karl Storz GmbH & Co., Tuttlingen, Germany). The inspection of the abdominal cavity with mobilization of the uterus disclosed a very large uterus. A 30-degree optic was then introduced to optimize the visualization (Figure 2A). A second and third trocar were inserted at the level of the vascular pedicle, and the fourth was inserted in the umbilicus. Dissection and sealing of the parametria, the round ligaments, and the ligament ovaria propria followed by the uterine vessels was performed with LigaSure (LigaSure™ 5 mm Blunt Tip, Covidien Belgium BVBA, Mechelen, Belgium). The first morcellation was performed with a cold laparoscopic knife (Chardonnens morcellation knife, Karl Storz GmbH & Co.) (Figure 2B).

The vaginal procedure started with opening the vagina with a circular incision around the cervix, dissecting the bladder, and opening the posterior fornix. Clamps were used on the sacro-uterine ligaments. Then, the morcellation was started using a knife and a tenaculum clamp. This maneuver took around two-thirds of the operating time. The vaginal cuff was closed and attached to the sacro-uterine ligaments. There were no complications and the operating time was 270 min. The blood loss was 900 mL and no blood transfusion was required. The surgical specimen weighed 2,802 g and the pathologic analysis resulted

in benign leiomyoma. The patient was discharged in the 2nd postoperative day.

DISCUSSION

It is not uncommon for a surgeon to be able to perform the entire laparoscopic hysterectomy using three 5-mm ports and then a larger abdominal incision to remove the surgical specimen.¹⁸ Most of the gynecologic surgeons will not remove a uterus weighing > 300 g either via the vagina or by the LAVH technique.⁷ Uteri > 300 g are hard to pull out through the vagina without any incision.¹⁹

Wattiez et al.⁷ first introduced several modifications to the current technique for LH for large uterus. The key modifications consisted of a higher insertion of the optic cannula with consideration of an open abdominal entry to minimize the risk of lacerating the uterus, and the 30-degree optic can ensure better visualization of uterine pedicles.⁷ The same technique was used in this case report.

Wattiez et al.⁷ reported that LH can be successfully carried out in most women with an enlarged uterus (ranging from 500 g to 1230 g). Thirty-four women with a uterus weighting more than 500 g were compared with 68 women with a uterus weighting ≤ 300 g; both groups submitted to total LH. No difference was observed concerning the complication rate among both groups. The operative time was significantly higher ($p < 0.001$) in women with a very enlarged uterus compared with those with a smaller uterus. The rates of intraoperative and postoperative complications and

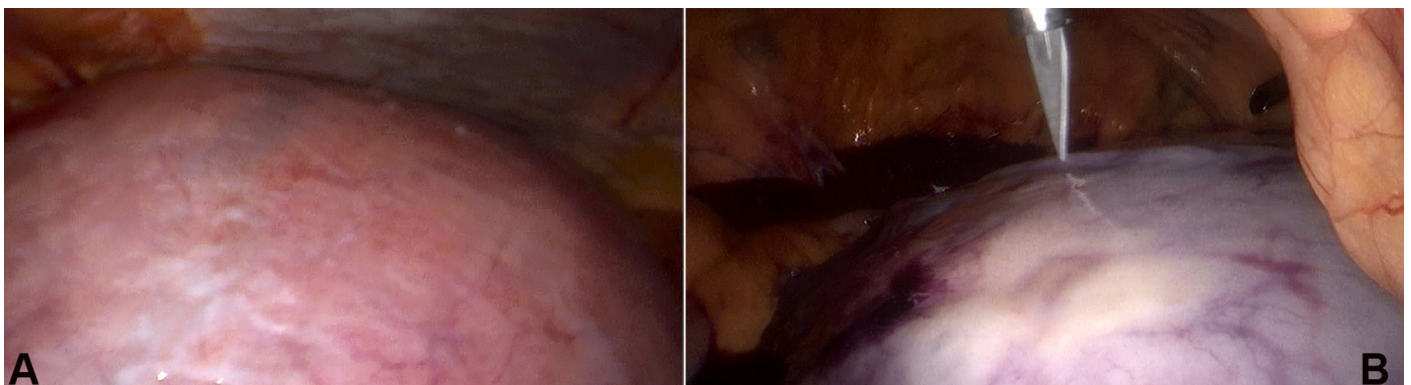


Figure 2. **A** - Large uterus. It is impossible to see it completely via a panoramic view; **B** - Morcellation with the cold laparoscopic knife.

the length of hospital stay were independent of the uterus size.¹³

Different laparoscopic techniques were developed for removing large uteri, including (i) intra-abdominal cutting of the uterus into pieces; (ii) morcellation (electromechanical,²⁰ in situ,¹⁴ or with a bowel bag technique for pelvic mass isolation, and then morcellation vaginally²¹); (iii) electrosurgery; and (iv) supracervical amputation followed by traquelectomy.²² The morcellation of a huge surgical specimen represents the limiting factor in reducing the operative time in LH.²³

An analysis of more than 6,000 laparoscopic hysterectomies from a multicenter series showed shorter operating times in LAVH compared with LH. This is consistent with previous reports, which also demonstrated reduced operative times in LAVH procedures.²⁴⁻²⁵ The difference is mainly due to the size of the uterus and the morcellation time.²⁶

Each morcellation type has pros and cons. In our case, the vaginal morcellation with the knife and tenaculum clamp technique was chosen to avoid the spread of myomatous cells in the abdominal cavity, despite the mass not showing malignant characteristics.

The vaginal fragmentation of a large uterus allows minimization of the spillage of surgical debris inside the abdominal cavity and avoids the enlargement of the ancillary ports to insert a 10-20 mm endoscopic morcellator.²³ The transvaginal closure of the vaginal stump was previously reported as a safe procedure.²⁷ The reduced abdominal incisions not only offer cosmetic advantages but also reduce the incidence of incisional hernia, which occurs in up to 3% using 12 mm trocars, but 0% using 5 mm trocars.²⁸

Walid and Heaton,²⁹ in a case report of a hysterectomy of a 3,000 g uterus, presented an operation time of 357 min and the estimated blood loss of 800 mL. Wattiez et al.⁷ showed a case in which the estimated blood loss was < 100 mL and the whole surgical time was 300 min. In this study, the operating time was 270 min and the blood loss was 900 mL. The operative time is longer compared to uteri of a smaller size⁷ or a laparotomy approach.³⁰ However, the time was similar to other studies with a large uterus because of the morcellation. The blood loss was higher than in the literature.^{7,29} These parameters are

probably because of the experience of surgeons and the characteristics of the uterus.

There are no definite guidelines about the better surgical approach for the treatment of a large uterus. It is still commonly accepted almost worldwide, that in everyday practice when the fundus of the uterus reaches the umbilicus the treatment of choice is open abdominal hysterectomy.²³

Skilled operators trained accordingly in endoscopic techniques with a commitment to reducing unnecessary open procedures is of utmost importance to obtain better results. The uterus size itself does not seem to be an absolute contraindication to endoscopic surgery, and the acquisition of adequate surgical skills to perform LH in cases of large uteri seems to be tightly connected to the policy and orientation of the medical centre.¹³

In conclusion, this case shows that the size of the uterus does not forbid the laparoscopic approach for hysterectomy. More randomized and multicenter studies are necessary before this technique can become routinely preconized.

REFERENCES

1. Whiteman MK, Hillis SD, Jamieson DJ, et al. Inpatient hysterectomy surveillance in the United States, 2000-2004. *Am J Obstet Gynecol.* 2008;198(1):34.e1-7. <http://dx.doi.org/10.1016/j.ajog.2007.05.039>. PMID:17981254.
2. Farquhar CM, Steiner CA. Hysterectomy rates in United States 1990-1997. *Obstet Gynecol.* 2002;99(2):229-34. [http://dx.doi.org/10.1016/S0029-7844\(01\)01723-9](http://dx.doi.org/10.1016/S0029-7844(01)01723-9). PMID:11814502.
3. Cramer SF, Patel A. The frequency of uterine leiomyomas. *Am J Clin Pathol.* 1990;94(4):435-8. PMID:2220671.
4. Wu JM, Wechter ME, Geller EJ, Nguyen TV, Visco AG. Hysterectomy rates in the United States, 2003. *Am J Obstet Gynecol.* 2007;110(5):1091-5. <http://dx.doi.org/10.1097/01.AOG.0000285997.38553.4b>. PMID:17978124.
5. Nieboer TE, Johnson N, Lethaby A, et al. Surgical approach to hysterectomy for benign gynaecological disease. *Cochrane Database Syst Rev.* 2009;(3):CD003677. PMID:19588344.
6. Johnson N, Barlow D, Lethaby A, Tavender E, Curr E, Garry R. Surgical approach to hysterectomy for benign gynaecological disease. *Cochrane Database Syst Rev.* 2006;2(2):CD003677. PMID:16625589.

7. Wattiez A, Soriano D, Fiaccavento A, et al. Total laparoscopic hysterectomy for very enlarged uteri. *J Am Assoc Gynecol Laparosc.* 2002;9(2):125-30. [http://dx.doi.org/10.1016/S1074-3804\(05\)60119-3](http://dx.doi.org/10.1016/S1074-3804(05)60119-3). PMID:11960035.
8. Reich H, DeCaprio J, McGLYNN FRAN. Laparoscopic hysterectomy. *J Gynecol Surg.* 1989;5(2):213-6. <http://dx.doi.org/10.1089/gyn.1989.5.213>.
9. Olsson JH, Ellstrom M, Hahlin M. A randomized prospective trial comparing laparoscopic and abdominal hysterectomy. *Br J Obstet Gynaecol.* 1996;103(4):345-50. <http://dx.doi.org/10.1111/j.1471-0528.1996.tb09740.x>. PMID:8605132.
10. Wong WS, Lee TC, Lim CE. Novel vaginal "paper roll" uterine morcellation technique for removal of large (>500g) uterus. *J Minim Invasive Gynecol.* 2010;17(3):374-8. <http://dx.doi.org/10.1016/j.jmig.2010.02.005>. PMID:20417430.
11. Kondo W, Bourdel N, Marengo F, et al. Is laparoscopic hysterectomy feasible for uteri larger than 1000g? *Eur J Obstet Gynecol Reprod Biol.* 2011;158(1):76-81. <http://dx.doi.org/10.1016/j.ejogrb.2011.03.027>. PMID:21555178.
12. Walid MS, Heaton RL. Laparoscopic extirpation of a 3kg uterus. *Arch Gynecol Obstet.* 2009;279(4):607-8. <http://dx.doi.org/10.1007/s00404-008-0827-9>. PMID:19011884.
13. Uccella S, Cromi A, Bogani G, Casarin J, Formenti G, Ghezzi F. Systematic implementation of laparoscopic hysterectomy independent of uterus size: clinical effect. *J Minim Invasive Gynecol.* 2013;20(4):505-16. <http://dx.doi.org/10.1016/j.jmig.2013.02.009>. PMID:23870240.
14. Chen SY, Chang DY, Sheu BC, et al. Laparoscopic assisted vaginal hysterectomy with in situ morcellation for large uteri. *J Minim Invasive Gynecol.* 2008;15(5):559-65. <http://dx.doi.org/10.1016/j.jmig.2008.06.002>. PMID:18657481.
15. Alperin M, Kivnick S, Poon KY. Outpatient laparoscopic hysterectomy for large uteri. *J Minim Invasive Gynecol.* 2012;19(6):689-94. <http://dx.doi.org/10.1016/j.jmig.2012.06.007>. PMID:23084671.
16. Walid MS, Heaton RL. Total laparoscopic hysterectomy for uteri over one kilogram. *JLS.* 2010;14(2):178-82. <http://dx.doi.org/10.4293/108680810X12785289143837>. PMID:20932364.
17. Sahin Y. Vaginal hysterectomy and oophorectomy in women with 12-20 weeks' size uterus. *Acta Obstet Gynecol Scand.* 2007;86(11):1359-69. <http://dx.doi.org/10.1080/00016340701657258>. PMID:17963064.
18. Ghezzi F, Raio L, Mueller MD, Gyr T, Buttarelli M, Franchi M. Vaginal extraction of pelvic masses following operative laparoscopy. *Surg Endosc.* 2014;16(12):1691-6. <http://dx.doi.org/10.1007/s00464-002-9043-z>. PMID:12140631.
19. Lin YS. New helical incision for removal of large uteri during laparoscopic assisted vaginal hysterectomy. *J Am Assoc Gynecol Laparosc.* 2004;11(4):519-24. [http://dx.doi.org/10.1016/S1074-3804\(05\)60086-2](http://dx.doi.org/10.1016/S1074-3804(05)60086-2). PMID:15701196.
20. Srouji SS, Kaser DJ, Gargiulo AR. Techniques for contained morcellation in gynecologic surgery. *Fertil Steril.* 2015;103(4):e34. <http://dx.doi.org/10.1016/j.fertnstert.2015.01.022>. PMID:25712576.
21. Walid MS, Heaton RL. Use of bowel bags in gynecologic laparoscopy. *Arch Gynecol Obstet.* 2009;279(5):777-9. <http://dx.doi.org/10.1007/s00404-008-0923-x>. PMID:19151992.
22. Nimaroff ML, Dimino M, Maloney S. Laparoscopic-assisted vaginal hysterectomy of large myomatous uteri with supracervical amputation followed by trachelectomy. *J Am Assoc Gynecol Laparosc.* 1996;3(4):585-7. [http://dx.doi.org/10.1016/S1074-3804\(05\)80171-9](http://dx.doi.org/10.1016/S1074-3804(05)80171-9). PMID:9050693.
23. Uccella S, Cromi A, Serati M, Casarin J, Sturla D, Ghezzi F. Laparoscopic hysterectomy in case of uteri weighting >1kg: a series of cases and review of the literature. *J Minim Invasive Gynecol.* 2014;21(3):460-5. <http://dx.doi.org/10.1016/j.jmig.2013.08.706>. PMID:24012921.
24. Shin JW, Lee HH, Lee SP, Park CY. Total laparoscopic hysterectomy and laparoscopy-assisted vaginal hysterectomy. *JLS.* 2011;15(2):218-21. <http://dx.doi.org/10.4293/108680811X13071180406394>. PMID:21902979.
25. Drahonovsky J, Haakova L, Otcenasek M, Krofta L, Kucera E, Feyereisl J. A prospective randomized comparison of vaginal hysterectomy, laparoscopically assisted vaginal hysterectomy, and total laparoscopic hysterectomy in women with benign uterine disease. *Eur J Obstet Gynecol Reprod Biol.* 2010;148(2):172-6. <http://dx.doi.org/10.1016/j.ejogrb.2009.10.019>. PMID:19926201.
26. Chou LY, Sheu BC, Chang DY, et al. Operating time and blood loss during laparoscopic-assisted vaginal hysterectomy with in situ morcellation. *Acta Obstet Gynecol Scand.* 2011;90(9):985-9. <http://dx.doi.org/10.1111/j.1600-0412.2011.01196.x>. PMID:21615713.
27. Uccella S, Ceccaroni M, Cromi A, et al. Vaginal cuff dehiscence in a series of 12,398 hysterectomies: effect of different types of colpotomy and vaginal closure. *Obstet Gynecol.* 2012;120(3):516-23. <http://dx.doi.org/10.1097/AOG.0b013e318264f848>. PMID:22914459.
28. Kadar N, Reich H, Liu CY, Manko GF, Gimpelson R. Incisional hernias after major laparoscopic gynaecologic procedures. *Am J Obstet Gynecol.* 1993;168(5):1493-1495.

- [http://dx.doi.org/10.1016/S0002-9378\(11\)90787-X](http://dx.doi.org/10.1016/S0002-9378(11)90787-X). PMID:8498433.
29. Walid MS, Heaton RL. Laparoscopic extirpation of a 3-Kg uterus. *Arch Gynecol Obstet.* 2009;279(4):607-8. <http://dx.doi.org/10.1007/s00404-008-0827-9>. PMID:19011884.
30. Raju KS, Auld BJ. A randomised prospective study of laparoscopic vaginal hysterectomy versus abdominal hysterectomy each with bilateral salpingo-oophorectomy. *BJOG.* 1994;101(12):1068-71. <http://dx.doi.org/10.1111/j.1471-0528.1994.tb13583.x>. PMID:7826960.

Conflict of interest: None

Submitted on: December 28th, 2015

Accepted on: February 11th, 2016

Correspondence

Beatriz H. Kehde

Rua Correia Salgado, 160 - São Paulo/SP – Brazil

CEP: 04267-010

Phone: +55 (11) 99962-7979 / Fax: +55 (11) 3209-4416

E-mail: biakehde@gmail.com; bia_kehde@yahoo.com.br